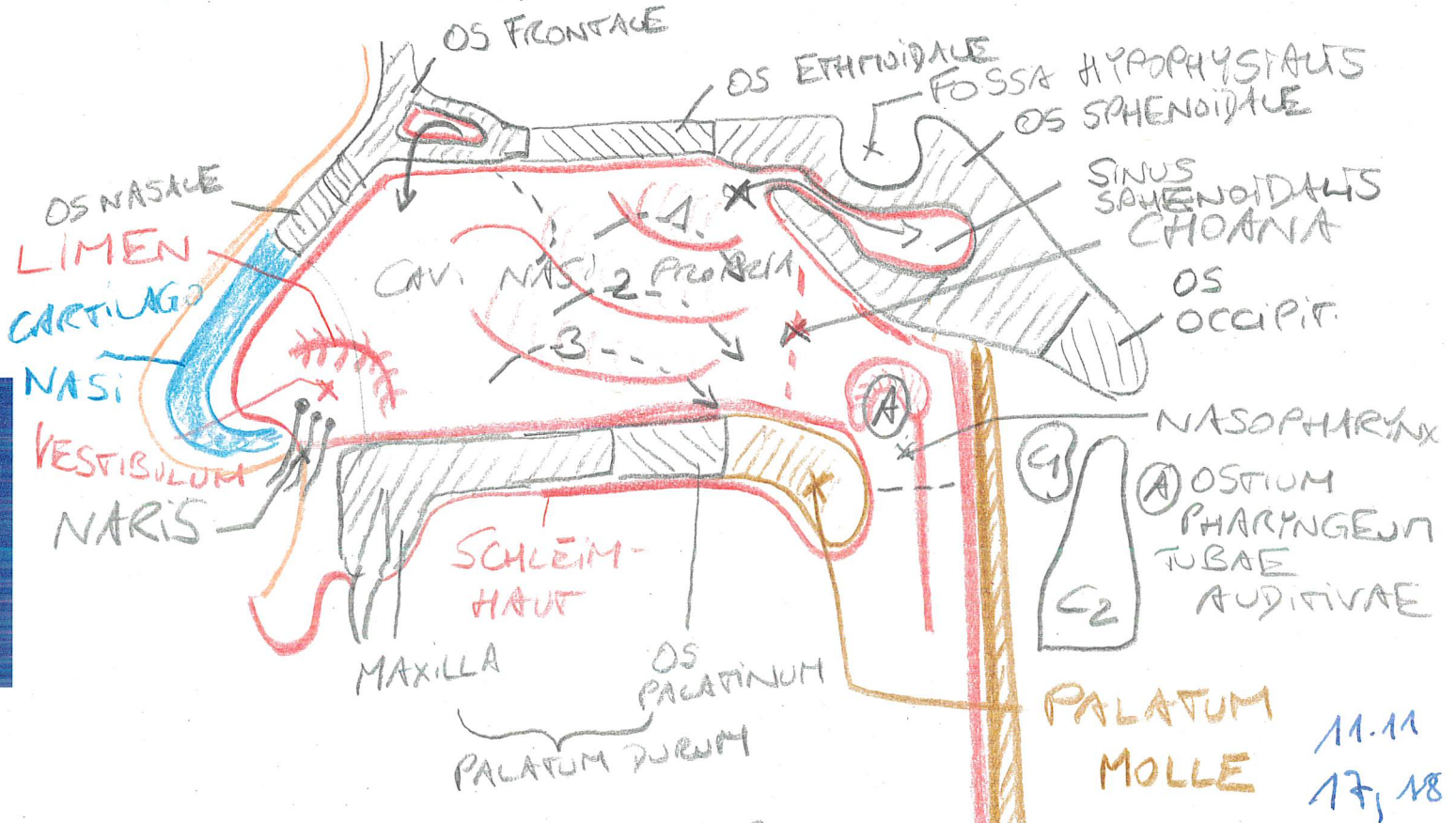


OBERER ATRIENRAUM
SAGITALSCHNITT
LAT. NASENWAND d. re. CAV. NASI



- 1... CONCHA NASALIS SUP.
---> MEATUS NASI SUP. -> CELLULAE ETHM. POST.
- 2... CONCHA NASALIS MEDIA
---> MEATUS NASI MEDIUS -> SINUS FRONTALIS
 ↳ SINUS MAXILLARIS
 ↳ CELLULAE ETHM. ANTT.,
 BULLA ETHMOIDALIS
- 3... CONCHA NASALIS INF.
---> MEATUS NASI INF. ← CANALIS NASOLACRIMALIS
 X RECESSUS SPHENOETHMOIDALIS
 ↳ SINUS SPHENOIDALIS

CAV. NASI:

SCHLEIMHAUT:

VESTIBULUM: MEHRSCH. UNVERHORN. T.

CAV. NASI PROPRIA:

↳ REGIO RESPIR.: FLIMMEREPITHEL
↳ REGIO OLFACTORIA: RIECHEPITHEL

BV.: A. MAXILLARIS ← A. CAR. EXT.

ABFLUSS.: PLEXUS VENOSI → V. MAXILLARIS
V. IUG. EXT. / INT. ↙

PHARYNX:

I PARS NASALIS - NASOPHARYNX - EPIPHARYNX
← PALATUM MOLLE

II PARS ORALIS - OROPHARYNX - MESOPHARYNX
← OBERRAND d. EPIGLOTTIS

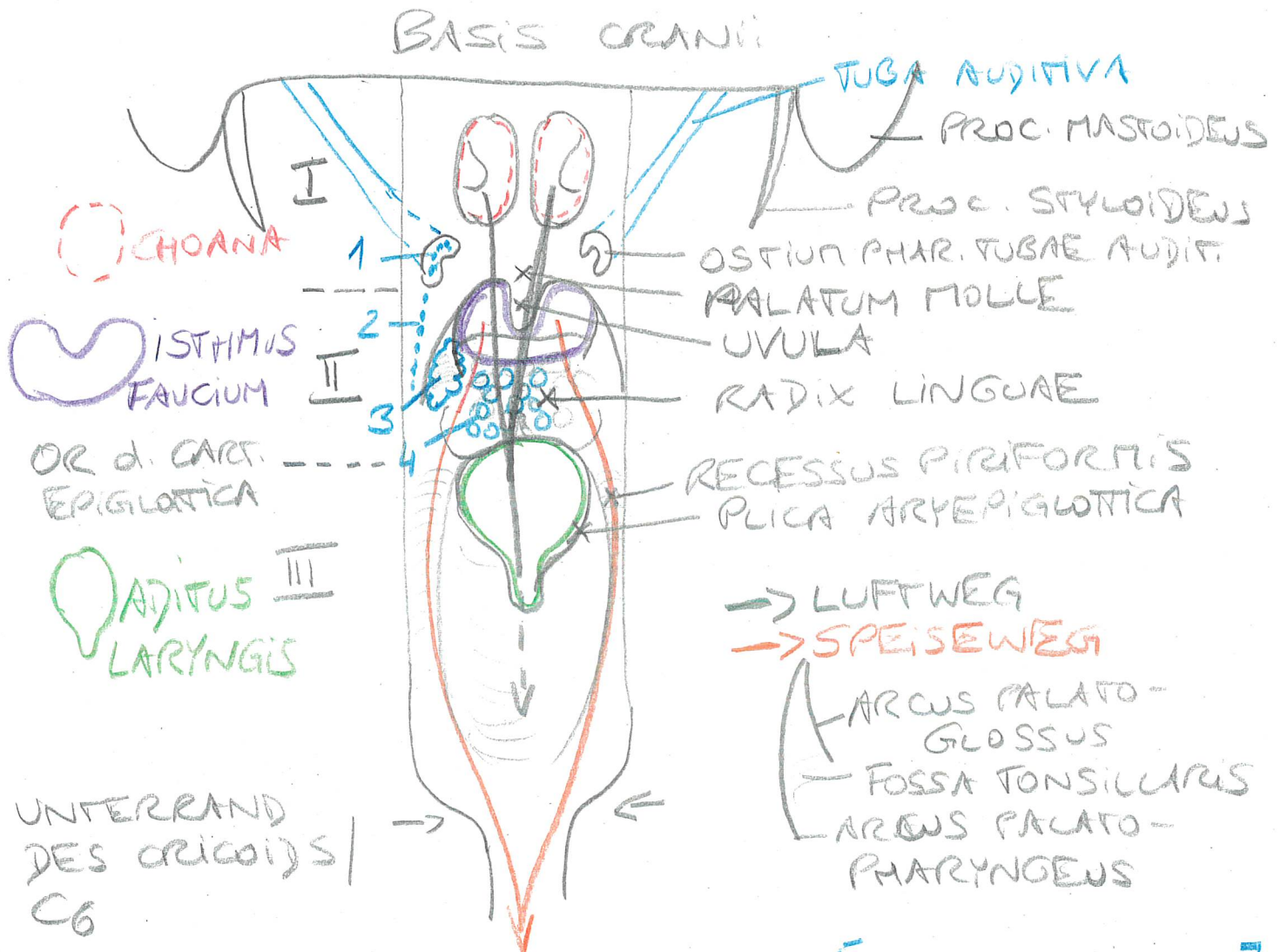
III PARS LARYNGEA - LARYNGOPHARYNX - HYPOPHARYNX

SCHLUCKAKT

QUERGESTR. MUSK. [= SKELLETMUSK.]

↳ SCHLUNDSCHNÜRER [CONSTRICTORES]
↳ SCHLUNDHEBER [LEVATORES]

PHARYNX u. DORS: ERÖFFNET



1-4: TONSILLAE [LYMPHAT. ORGANE]

"ANGINA"

1... TONSILLA TUBARIA

2... TONS. PHARYNGEA

3... TONS. PALATINA

↳ "TONSILLEKTOMIE"

4... TONS. LINGUALIS

SCHLEIMHAUT:

I... RESPIR. FÜNNEREPITHEL

II + III ... MEHRSCH. UNTERKONTES PLATTENEPITHEL

UNTERER AERENTRAKT:

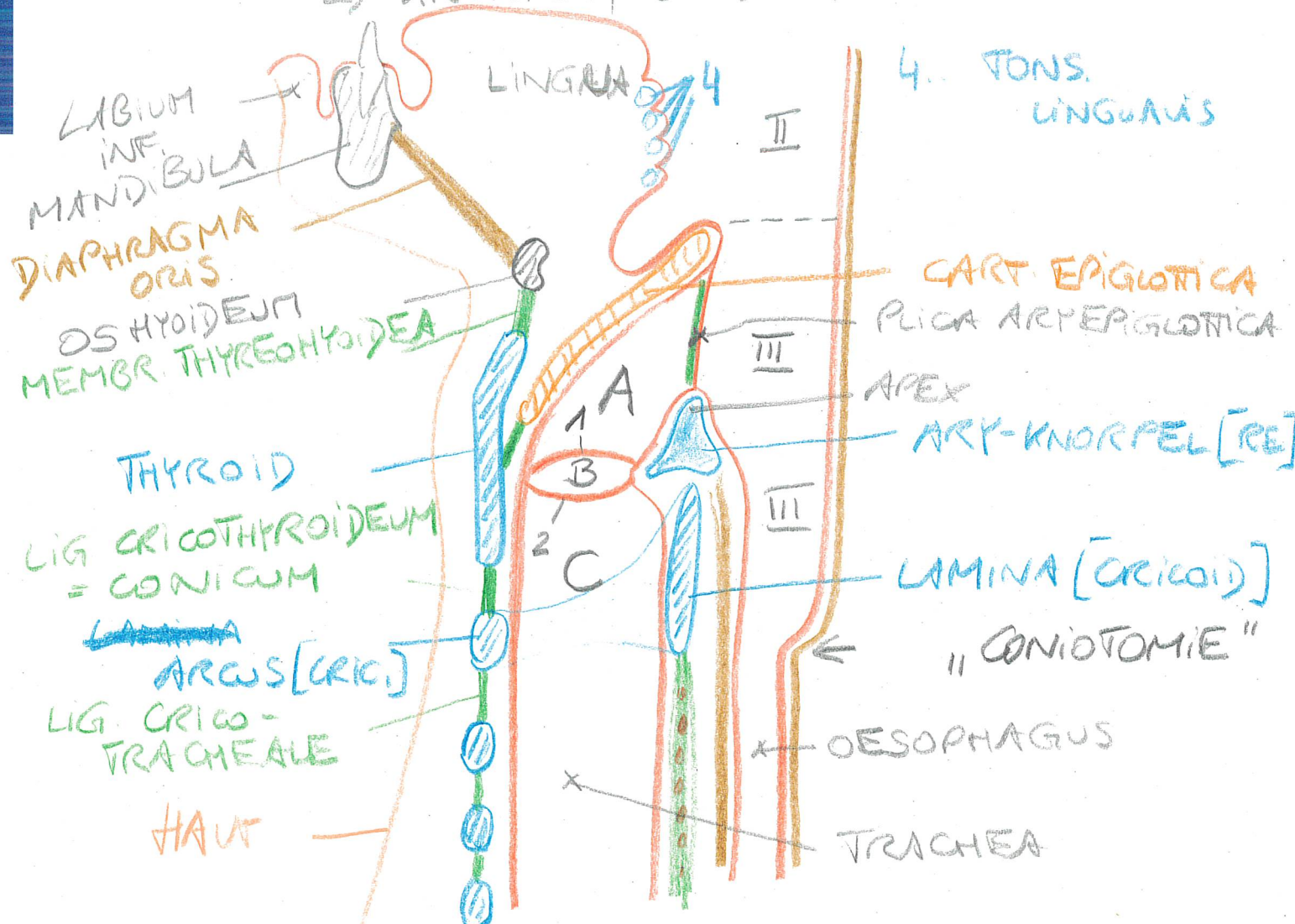
LARYNX: C₄ - C₆ ; LUFTWEG,
STIMMBILDUNG

KNORPELIGES GRUNDBERÜST.:

- HYALIN { 1x CARTILAGO THYROIDEA = THYROID
1x CART. CRICOIDEA = CRICOID
2x CART. ARYTAENOIDEA = "STELLKNORPEL"
- ELAST. 1x CART. EPIGLOTTICA = EPIGLOTTIS

OS HYOIDEUM

GLOTTIS: "STIMMBILDENDE APPARAT"
→ KNORPEL, BANDER, MUSKELN



STÜCKWERKE LARYNX:

A... VESTIBULUM

← 1... Plica vestibularis

B... VENTRICULUS LARYNGIS

← 2... Plica vocalis [Lig. vocale,
M. vocalis]

C... CAVITAS INFRAGLOTTICA

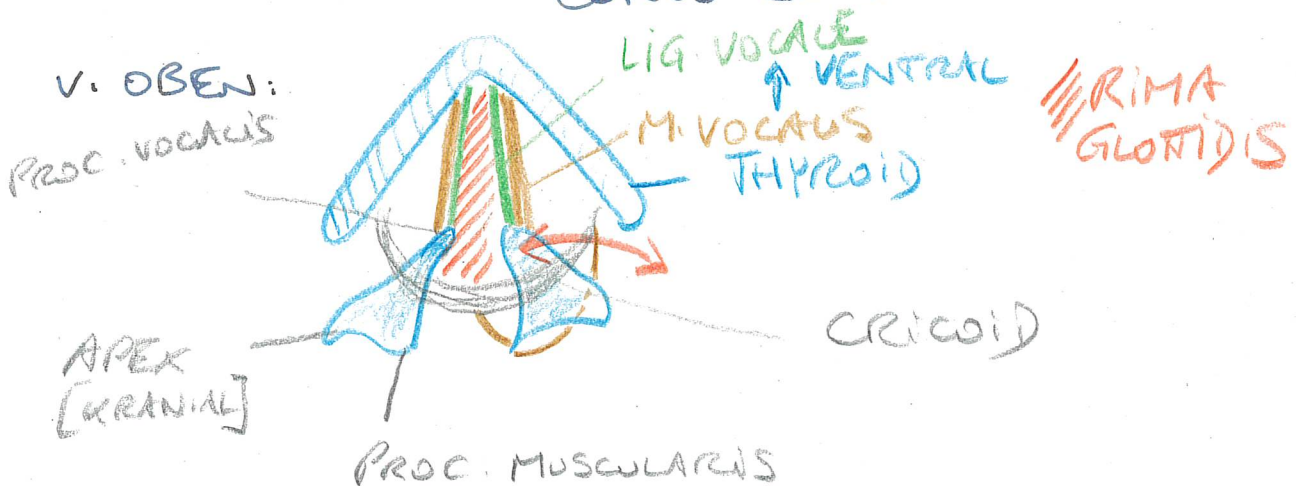
RESAR. FÜNNEREPITHEL

1+2: MEHRSCH. UNVERHORNT. PLATTENE.

RIMA GLOTTIDIS: STANNRITZE

ZW. PLICAE VOCALIS

~~GLOTTIS~~ GLOTTIS: Plica vocalis,
MEMBRANA QUADRANGULARIS,
CONUS ELASTICUS



BV.: A. CAR. EXT., A. SUBCLAVIA

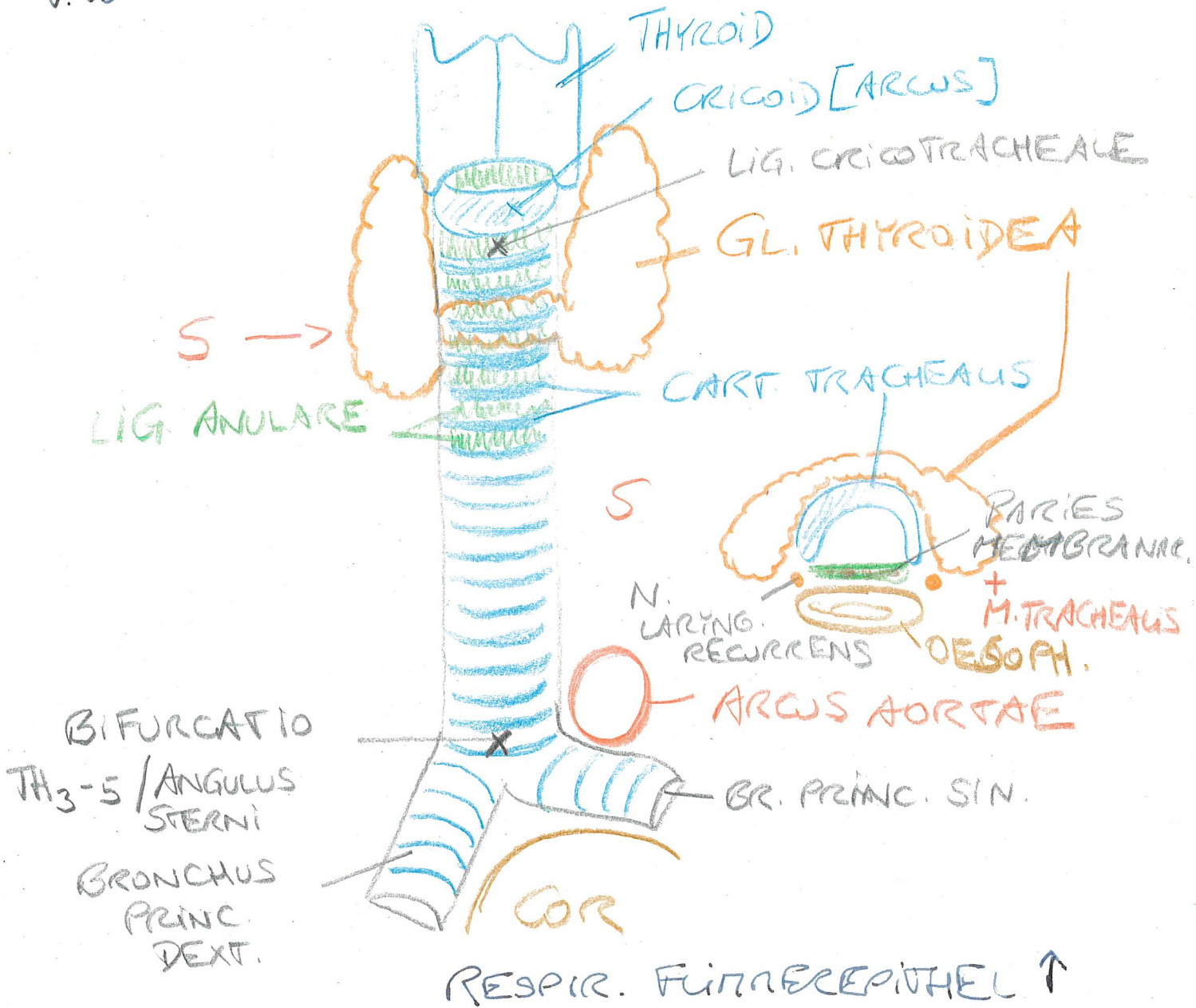
ABFLUSS: V. IUG. EXT. / INT.

INN.: N. VAGUS

MUSK.: N. LARYNGEUS
RECURRENS

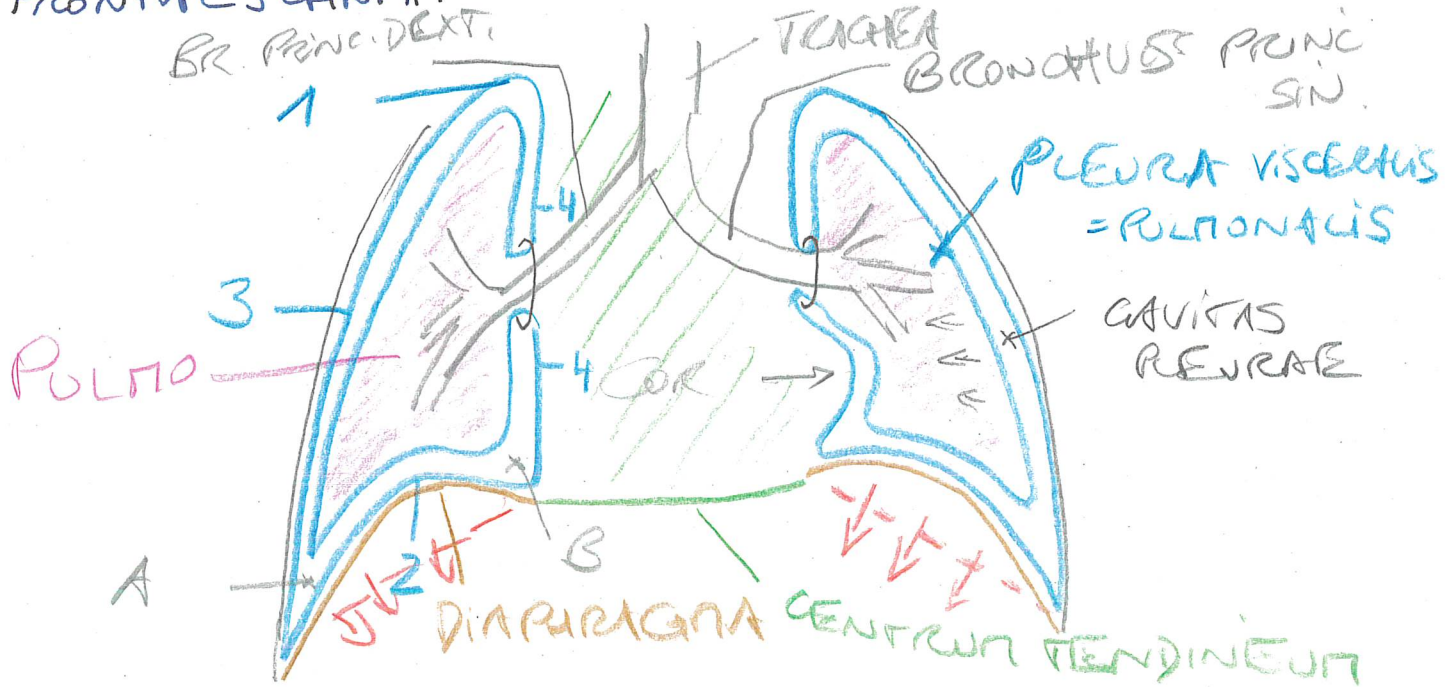
TRACHEA: 12-14 cm lang
16-20 KNORPELSPANGEN

V. 10



CAVITAS PLEURAE

FRONTALSCHNITT:
 BR. PRINC. DEXT.



MESOPNEUMONIA = LG. PULMONALE

1-4: PLEURA PARIETALIS

1... ~~AP~~ CUPULA

3... PL. COSTATUS

2... PL. DIAPHRAGMATICA

4... PL. MEDIASTINATUS

RECESSUS A... REC. COSTODIAPHRAGMATICUS

B... REC. DIAPHRAGMATICOMEDIASTINATUS

C... REC. COSTOMEDIASTINATUS

MUSKULATUR: - DIAPHRAGMA

↑ N. PHRENICUS [C4]

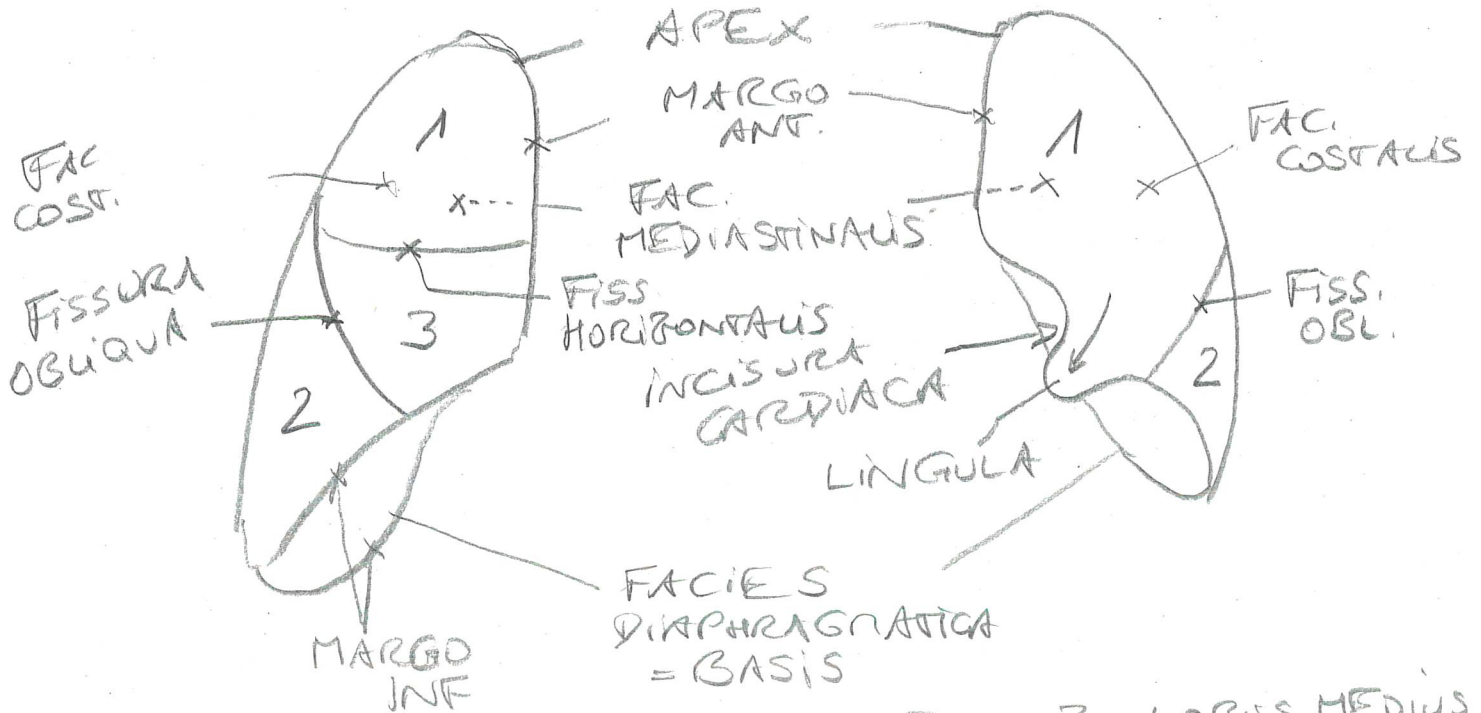
- MM. INTERCOSTALES

- ATTEMHILFSMUSK.

PULMO DEXT. et PULMO SIN.

RE

LI



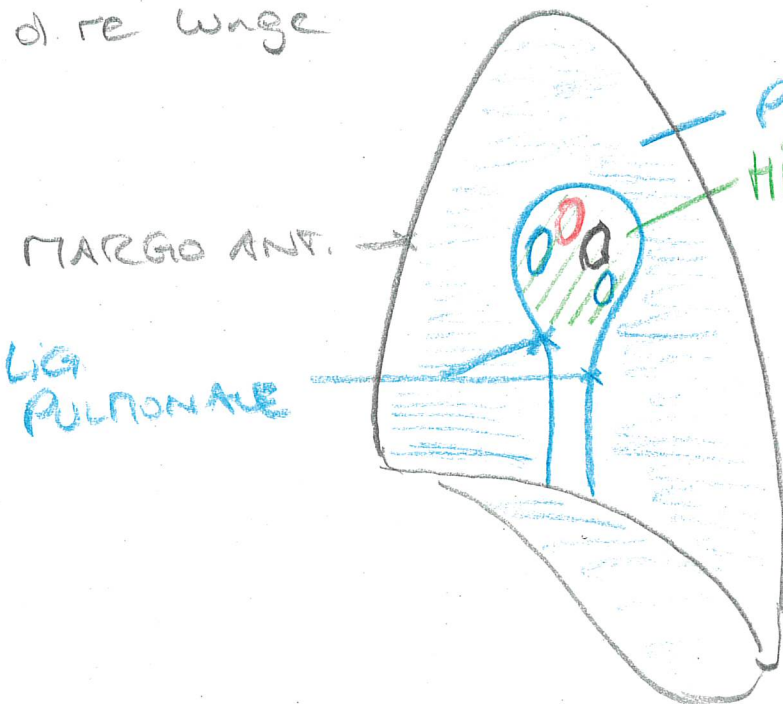
1... LOBUS SUP.
= OBERLAPPEN

2... LOBUS INF.
= UNTERLAPPEN

3... LOBUS MEDIUS
= MITTELLAPPEN

FAC. MEDIASTINALIS

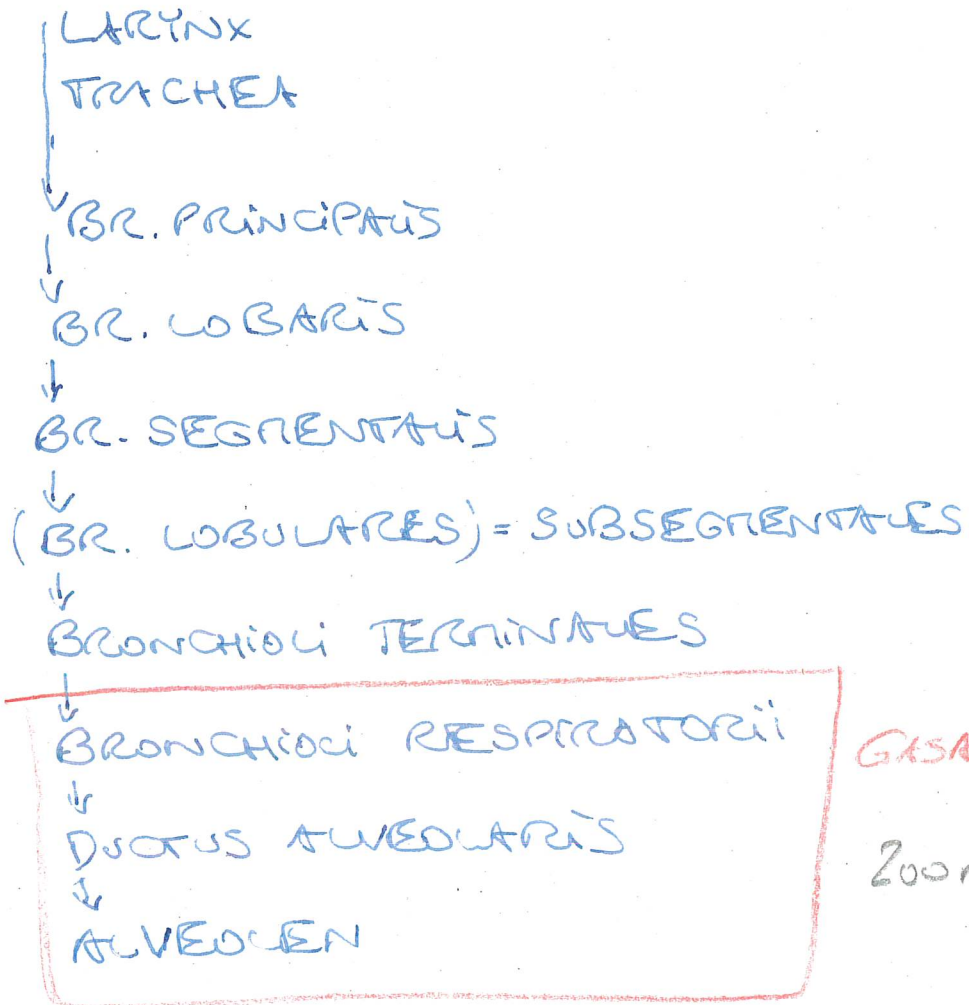
d. re. Wange



HILUM:.

- A. VISC. BRONCHUS PRINCIPALIS
 - A. PULMONALIS
 - V. PULMONALES
 - AA. BRONCHIALES
 - V. BRONCHIALES
- } VASA PRIVATA
- * VASA PUBLICA
LYMPHGEFÄSSE
VEGETATIVE NERVEN

ATEMWEGE:

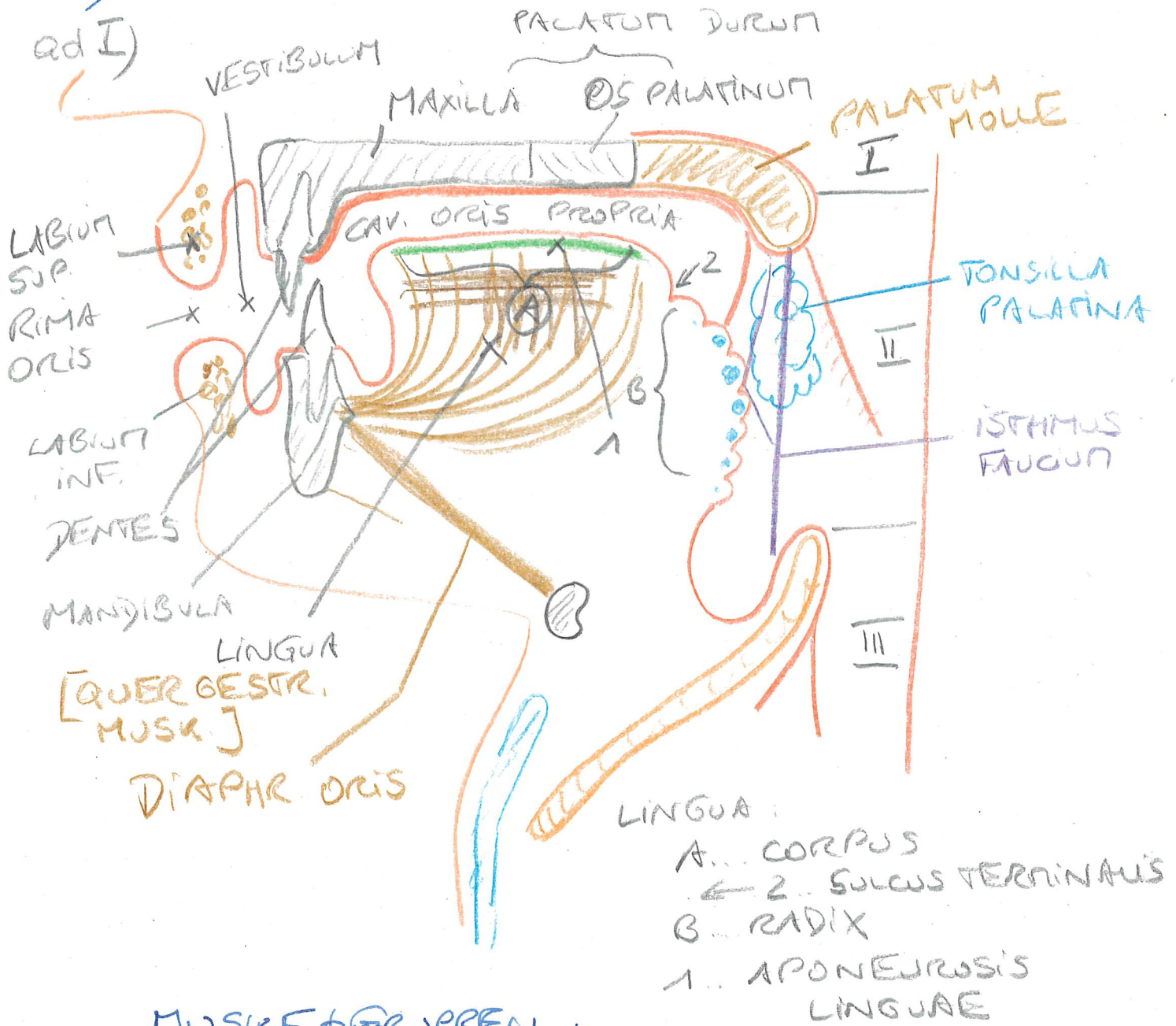


GASAUSTAUSCH

200m²

TRACTUS DIGESTORIUS

- I) KOPFDARM/KIEHENDARM: BIS INKL. PHARYNX
- II) RUMPFDARM: OESOPHAGUS → ANUS



MUSKELGRUPPEN

am KOPF:

* MIMISCHE MUSK.: ← N. FACIATIS VII

* KAUFUSK.: ← N. TRIGEMINUS V
N. MANDIBULARIS V/3

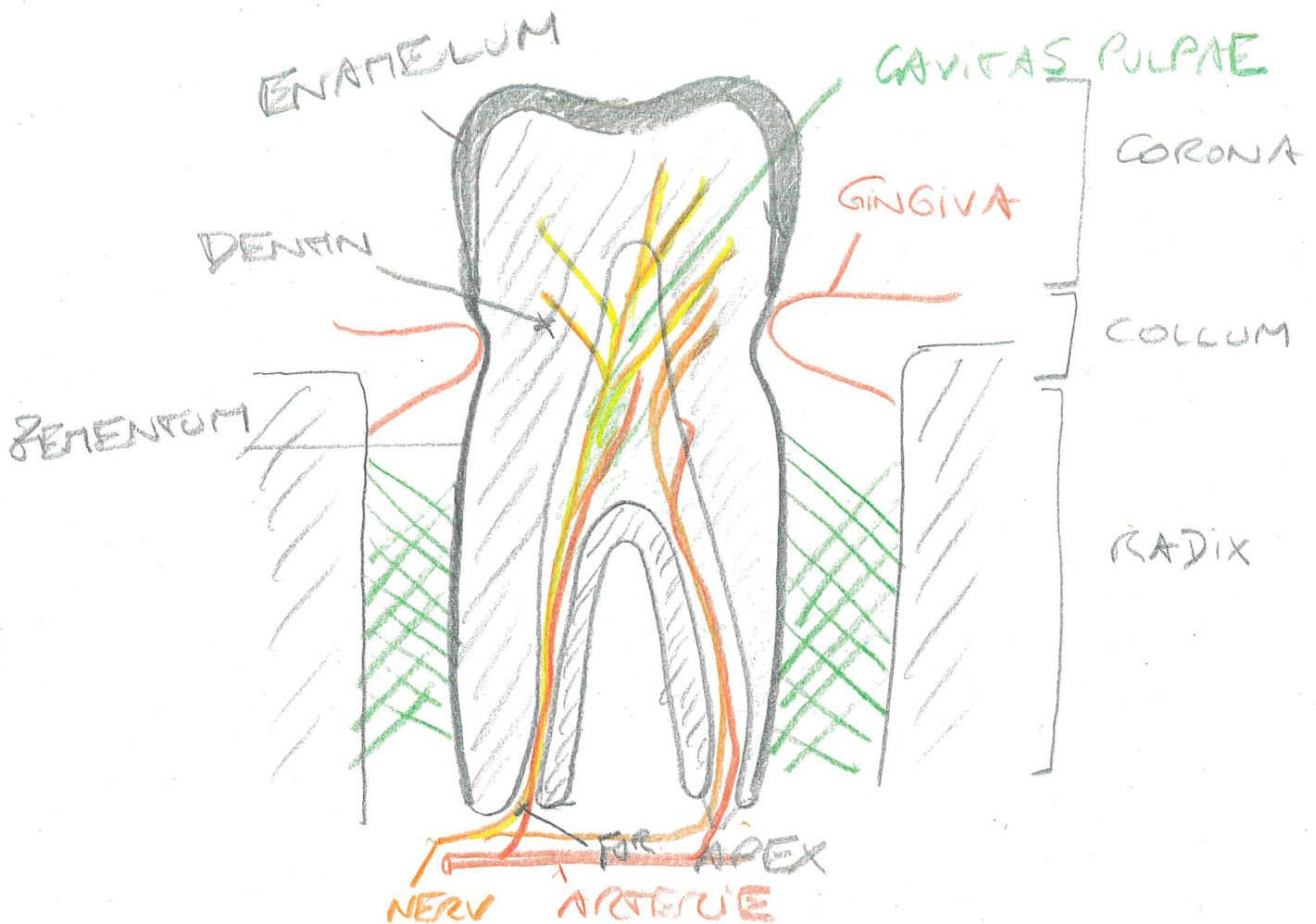
DENTES:

I) DENTES DECIDUI: 20 [5/QUADRANT]

II) DENTES PERMANENTES:
32 [8/QUADRANT]

- DENTES INCISIVI: 2
- DENS CANINUS: 1
- DENTES PREMOLARES: 2
- DENTES MOLARES: 3

GOMPHOSIS



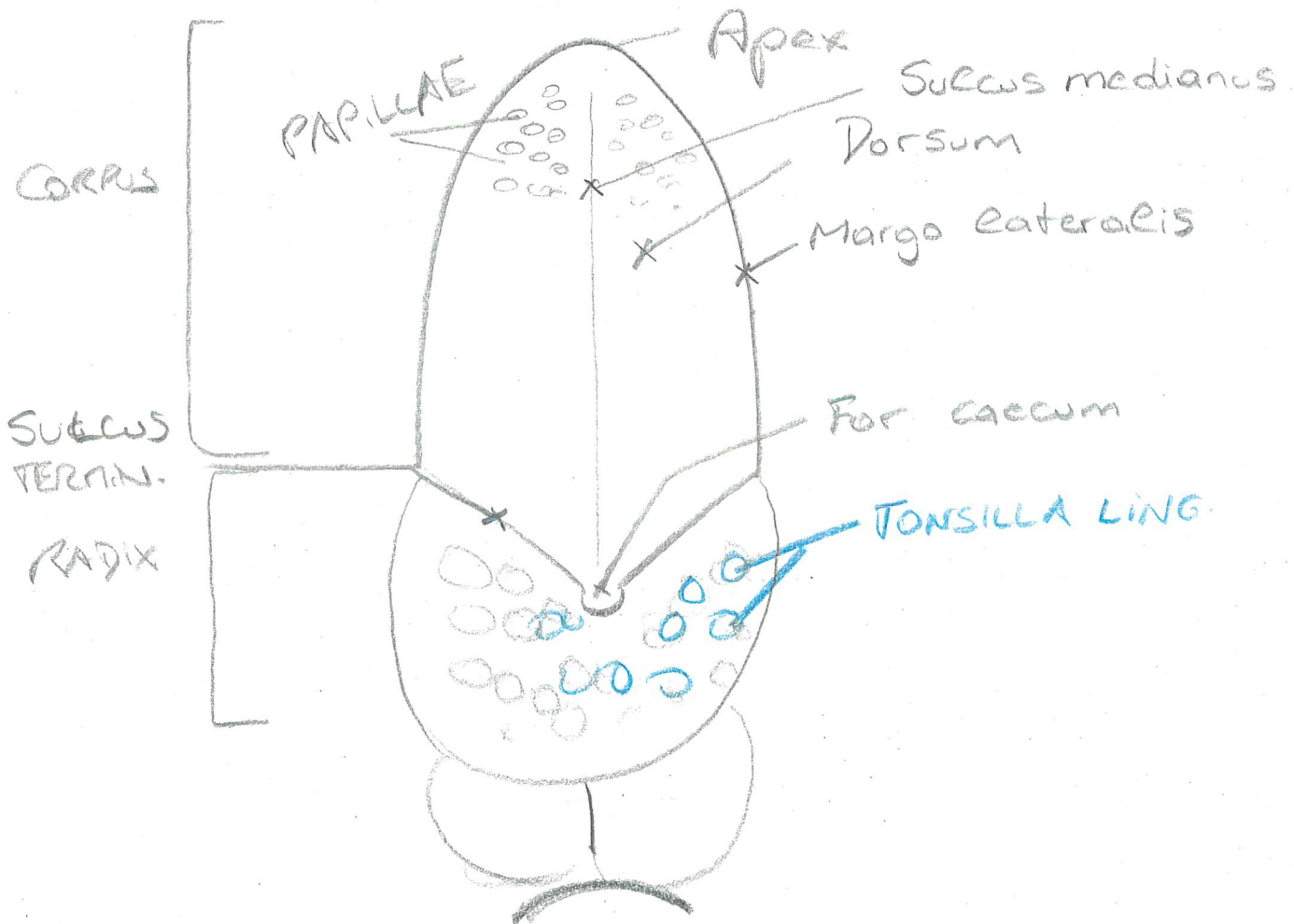
LINGUA / GLOSSA

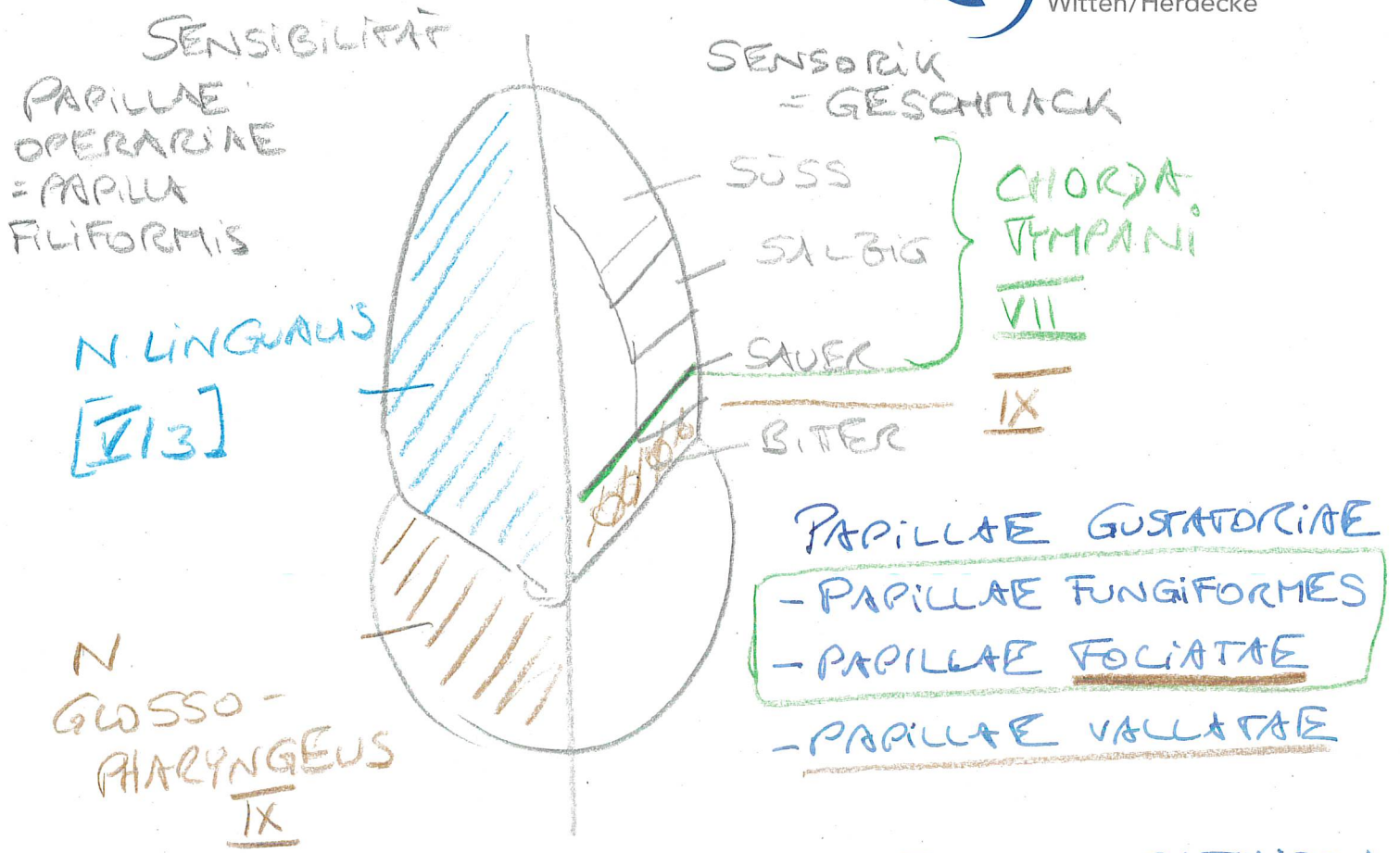
QUERG. MUSK: ← N. HYPOGLOSSUS XII

BINNENMUSK.

EXTERNER MUSK.

MEHRSCH. UNTERHORNT. EPITHEL





GLANDULAE SALIVARES: PARASYMPATHISCH

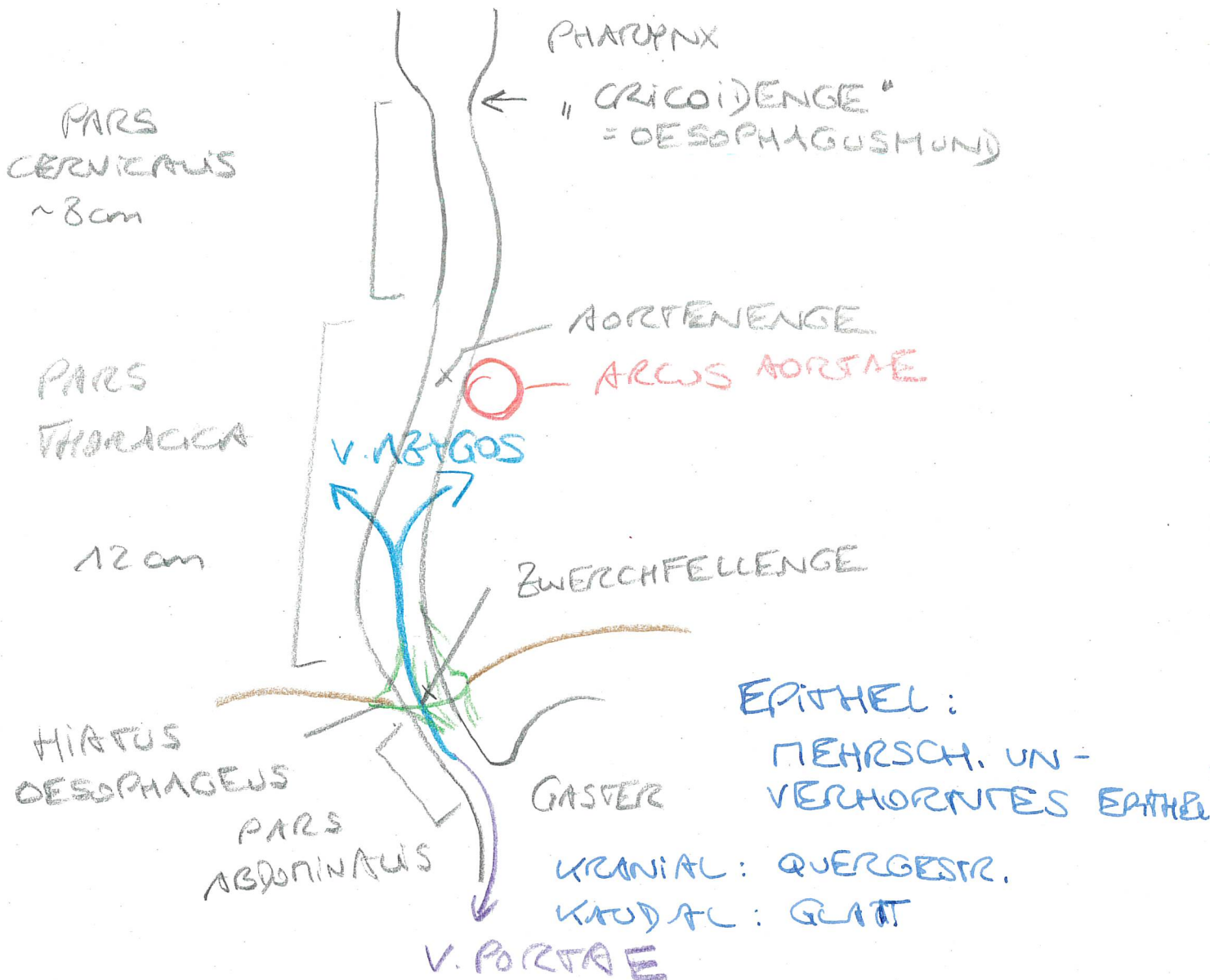
- 1) GL. PAROTIS [= PAROTIDEA]
 - SERÖS
 - DUCTUS PAROTIDEUS → VESTIBULUM ORIS
- 2) GL. SUBMANDIBULARIS + SUBLINGUALIS
 - SEROMUKÖS
 - DUCT. SUBMANDIBULARIS → CAV. ORIS PROPRIA
- 3) GL. LINGUALES ANT. + POST., PHARYNGEALES
 - MUKÖS

II) RUMPFDARM

- VORDERDARM
- MITTELARM
- ENDARM

OESOPHAGUS : ~ 25cm

V. VO



CAVITAS ABDOMINALIS et PELVIS

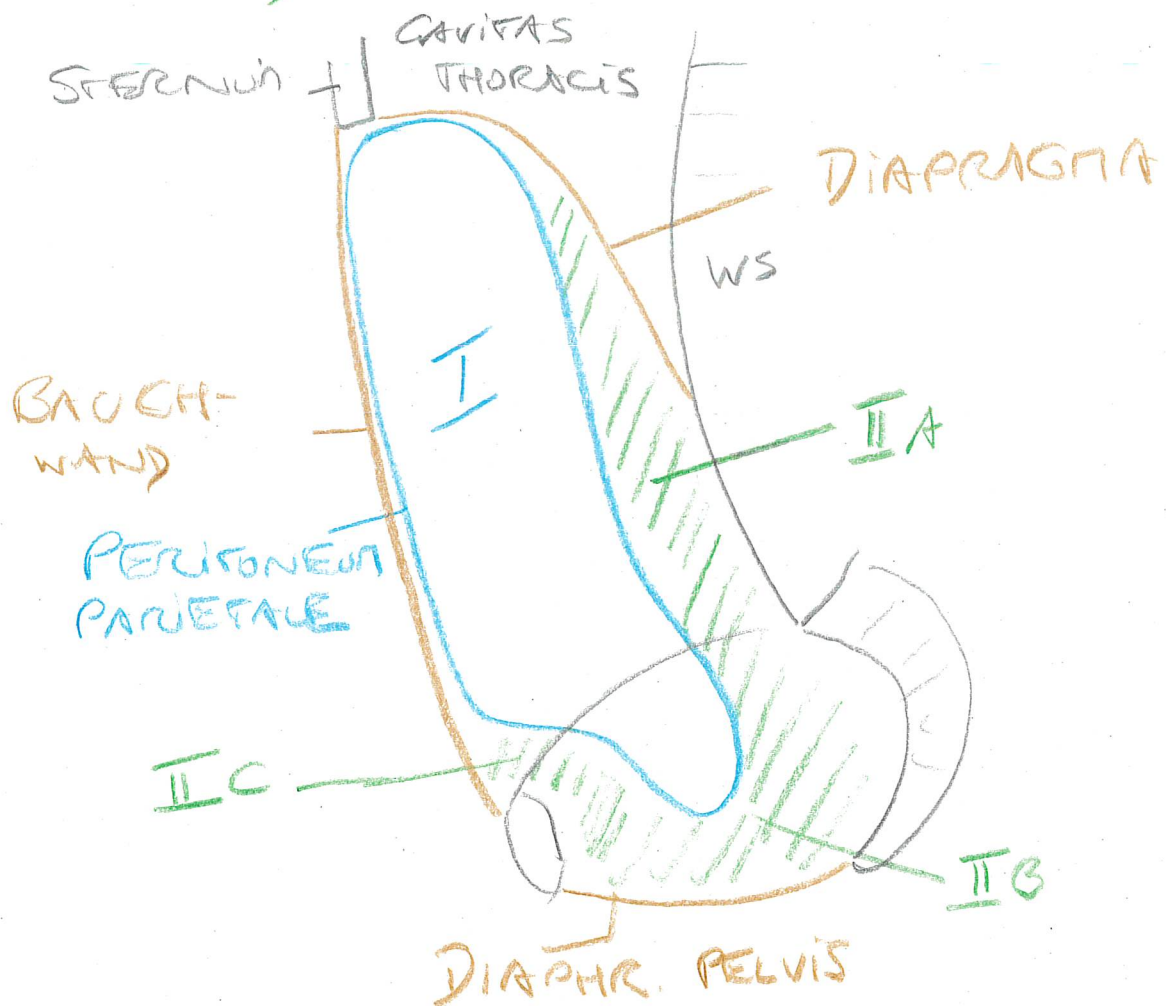
I) CAVITAS PERITONEALE
= BAUCHFELLENHÖHLE

II) SPATIUM EXTRAPERITONEALE

A) SP. RETROPERIT.

B) SP. SUBPERIT.

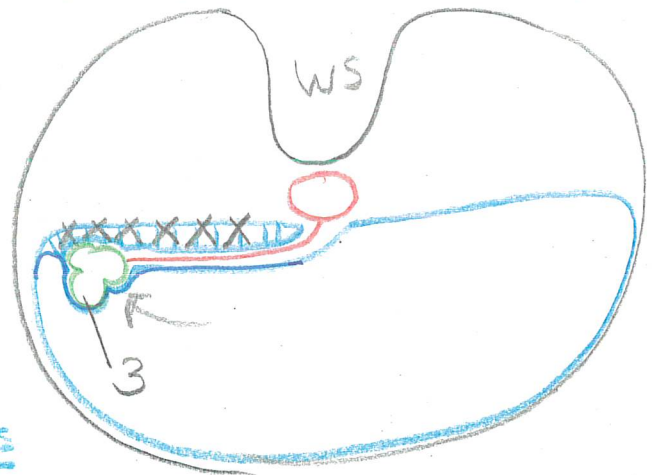
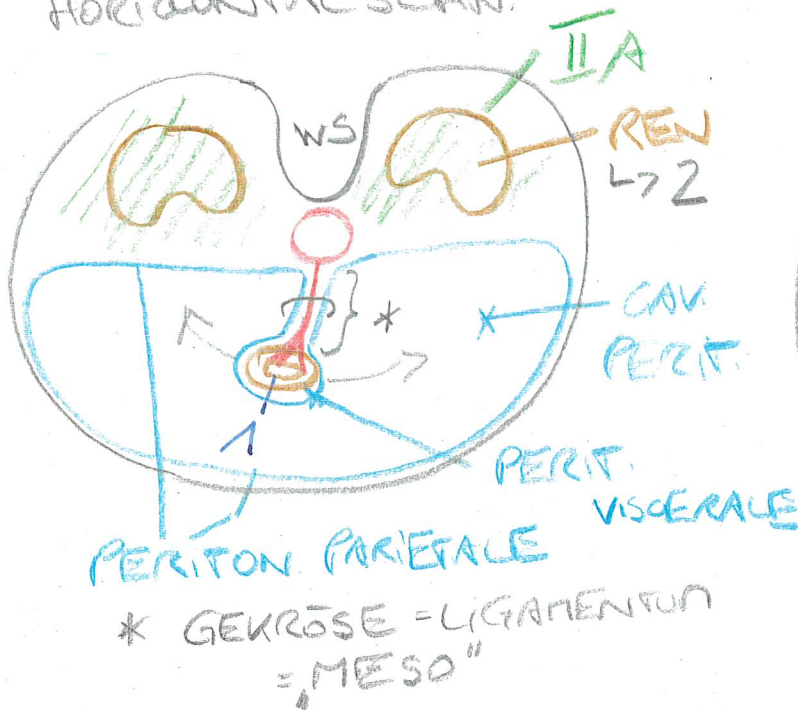
C) SP. PREPERIT.



PERITONEALITÄT:

- 1) INTRAPERITONEAL: "FREI BEWEGLICH"
an einem GEKÖSE ["LIGAMENTUM"]
- 2) EXTRAPERITONEAL: INNER AUSSERHAUS
- 3) SEKUNDÄR EXTRAPERITONEAL / RETROPERIT.
WAR 1) → ANGEWACHSEN! → 3

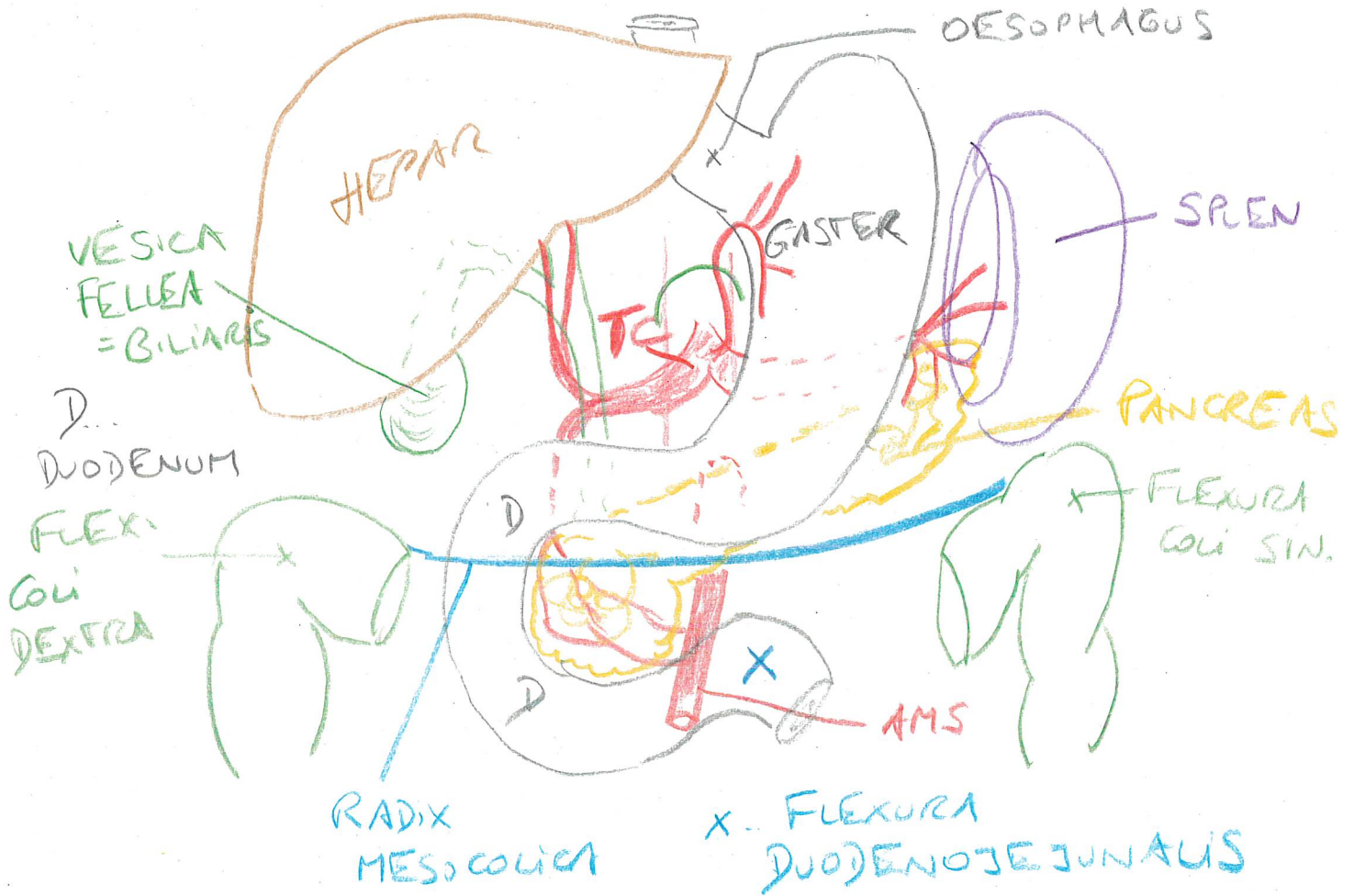
HORIZONTALSCHN.



CAVITAS PERITONEALIS:

- ↳ OBERBAUCH = DRÜSENBAUCH
- ← FLEXURA DUODENOJEJUNALIS;
RADIX MESOCOLICA
- ↳ UNTERBAUCH = DARMBAUCH

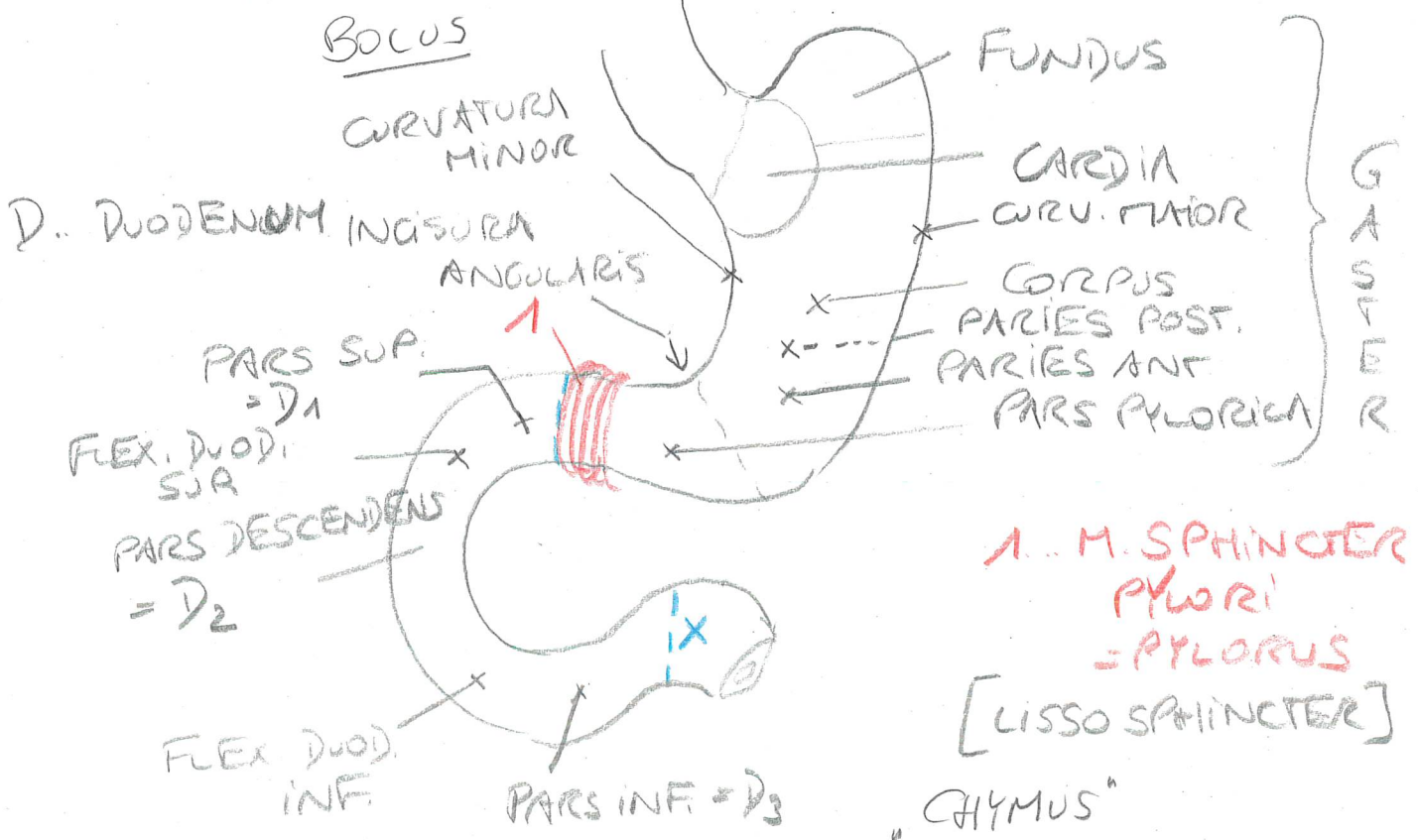
OBERBAUCH



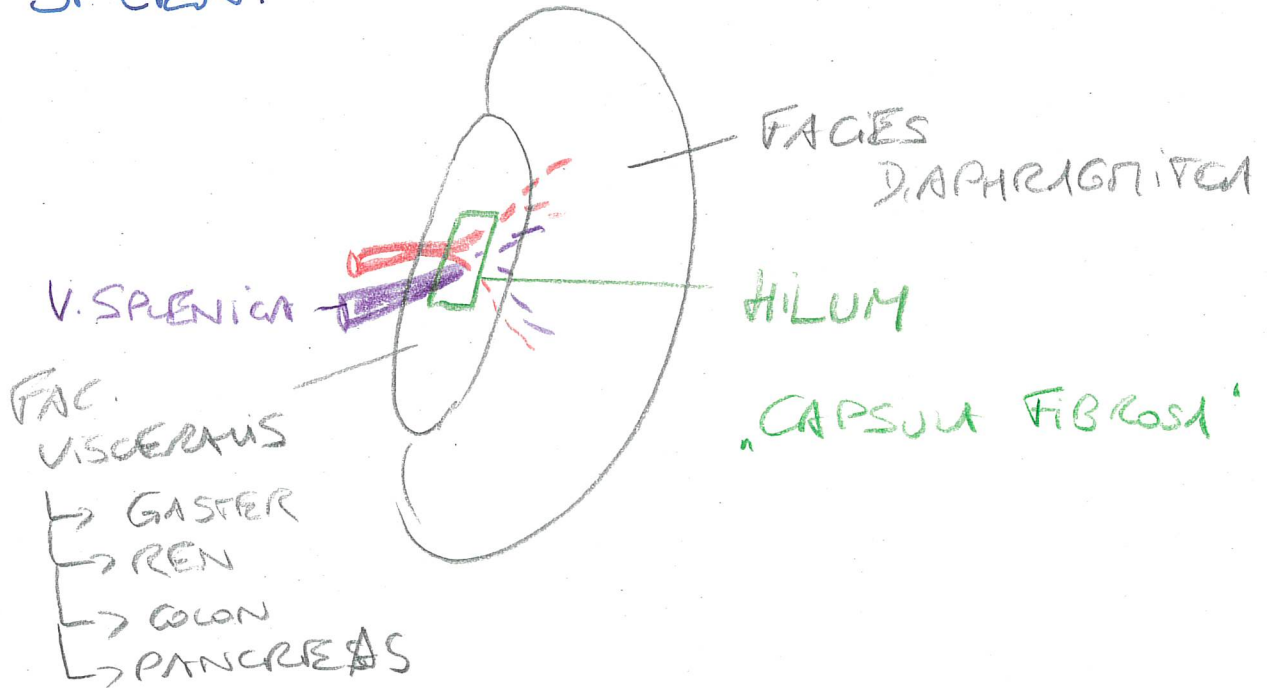
BV.: TRUNCUS COELIACUS
A. MESENT. SUP

GASTRER et DUODENUM

V.VO

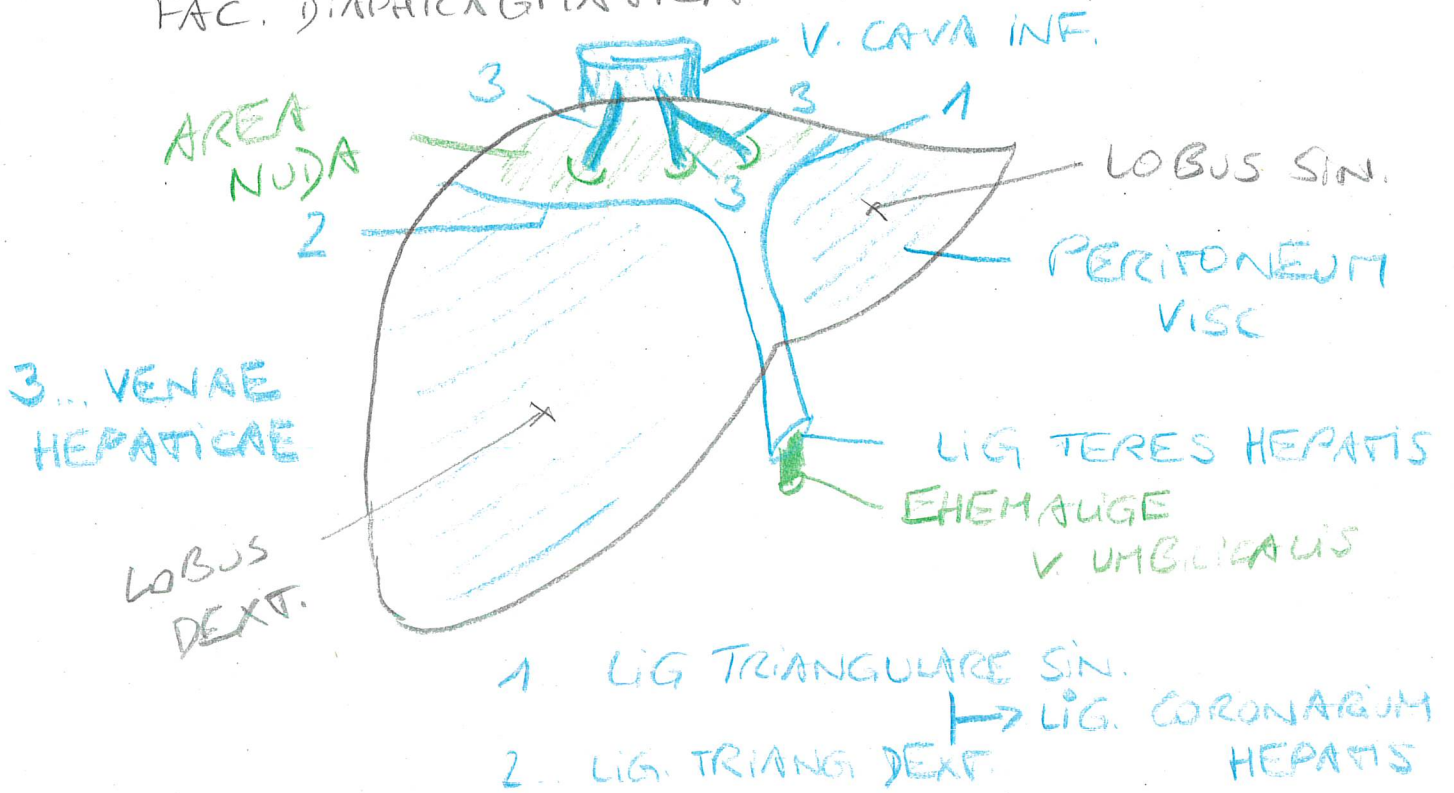


SPLEEN:

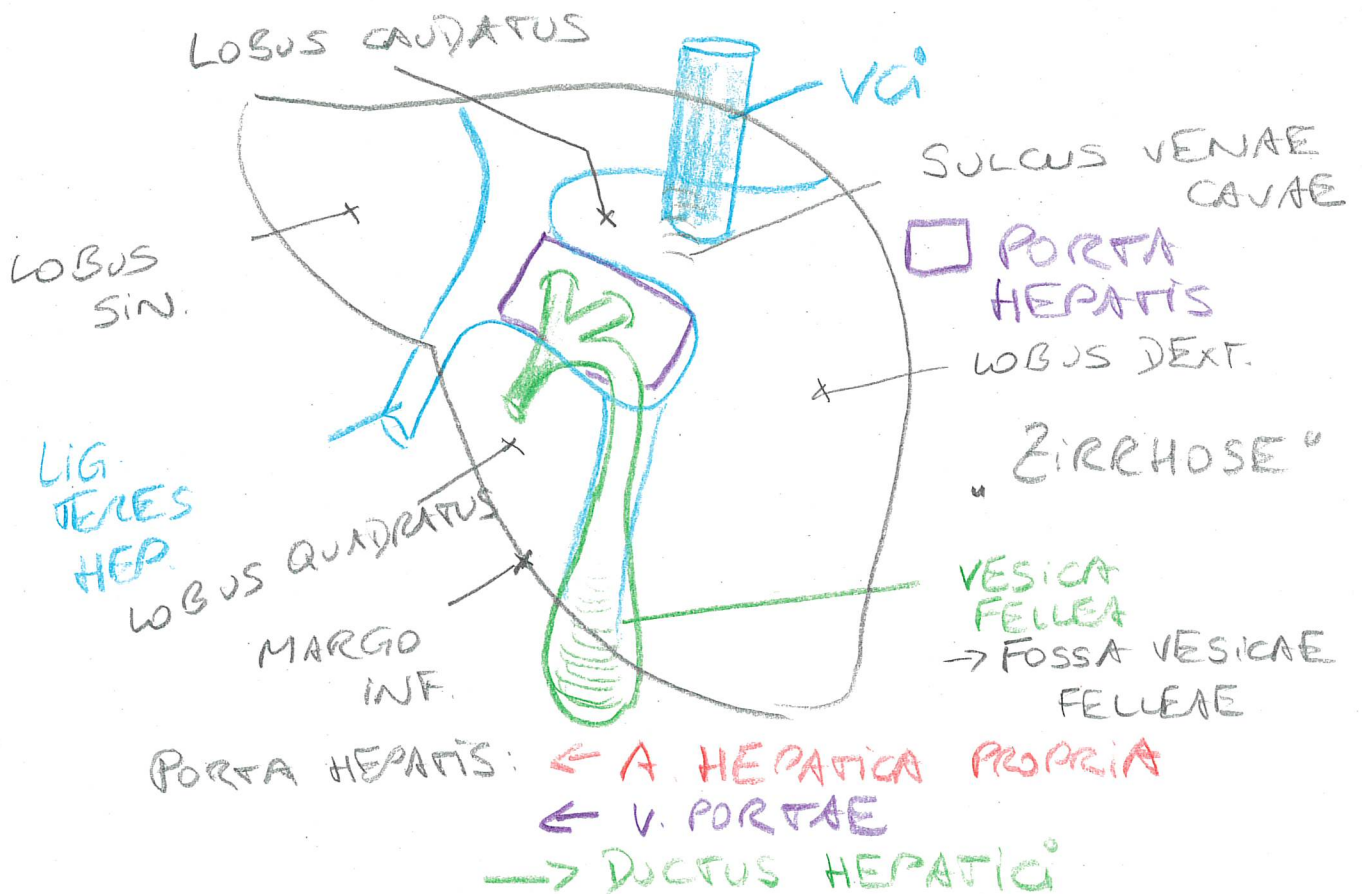


HEPAR:

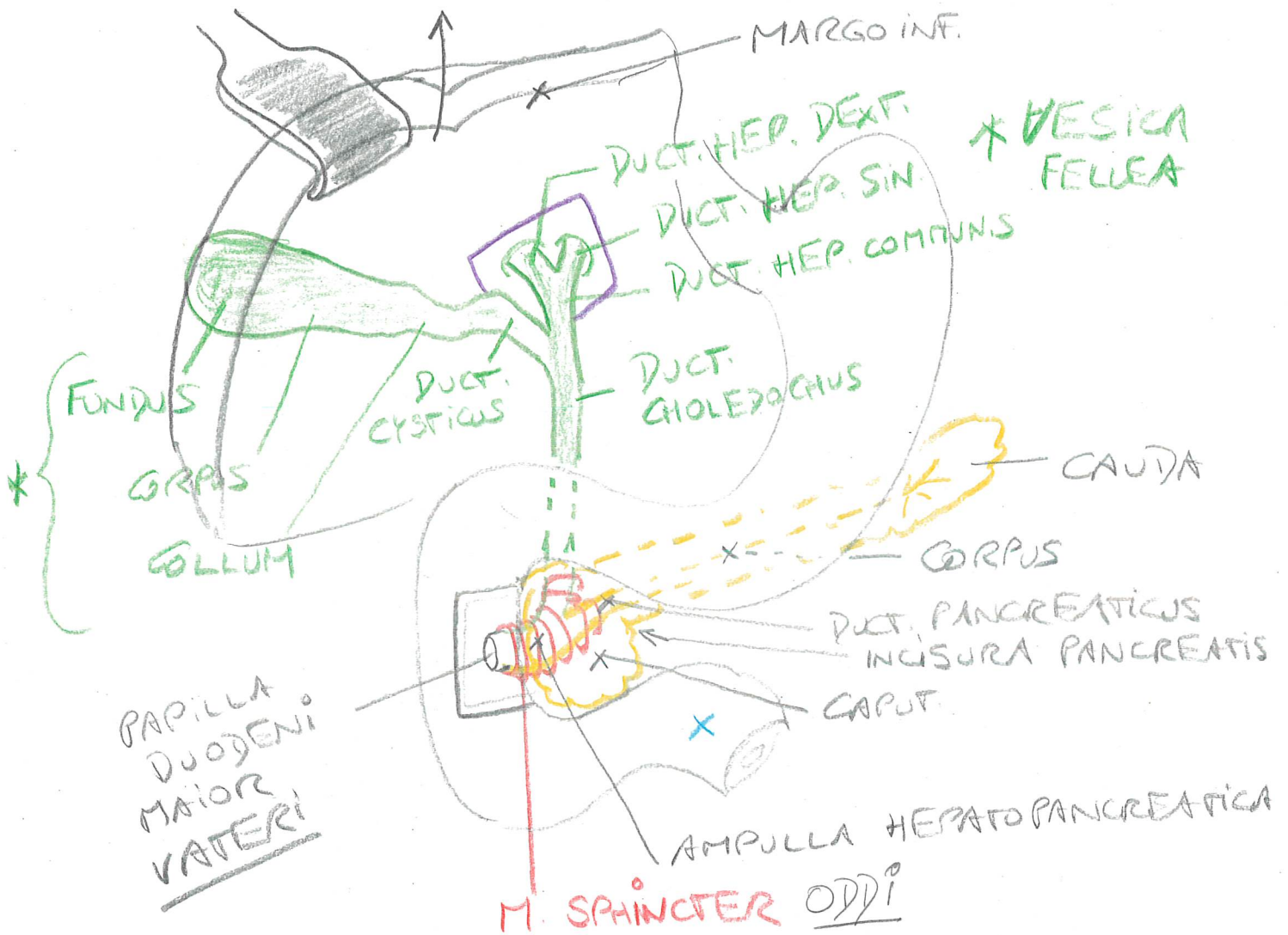
FAC. DIAPHRAGMATICA



FAC. VISC.: V. DORS.



VESICA FELLEA, EXTRAPER. GALLEWEGE
ET PANCREAS

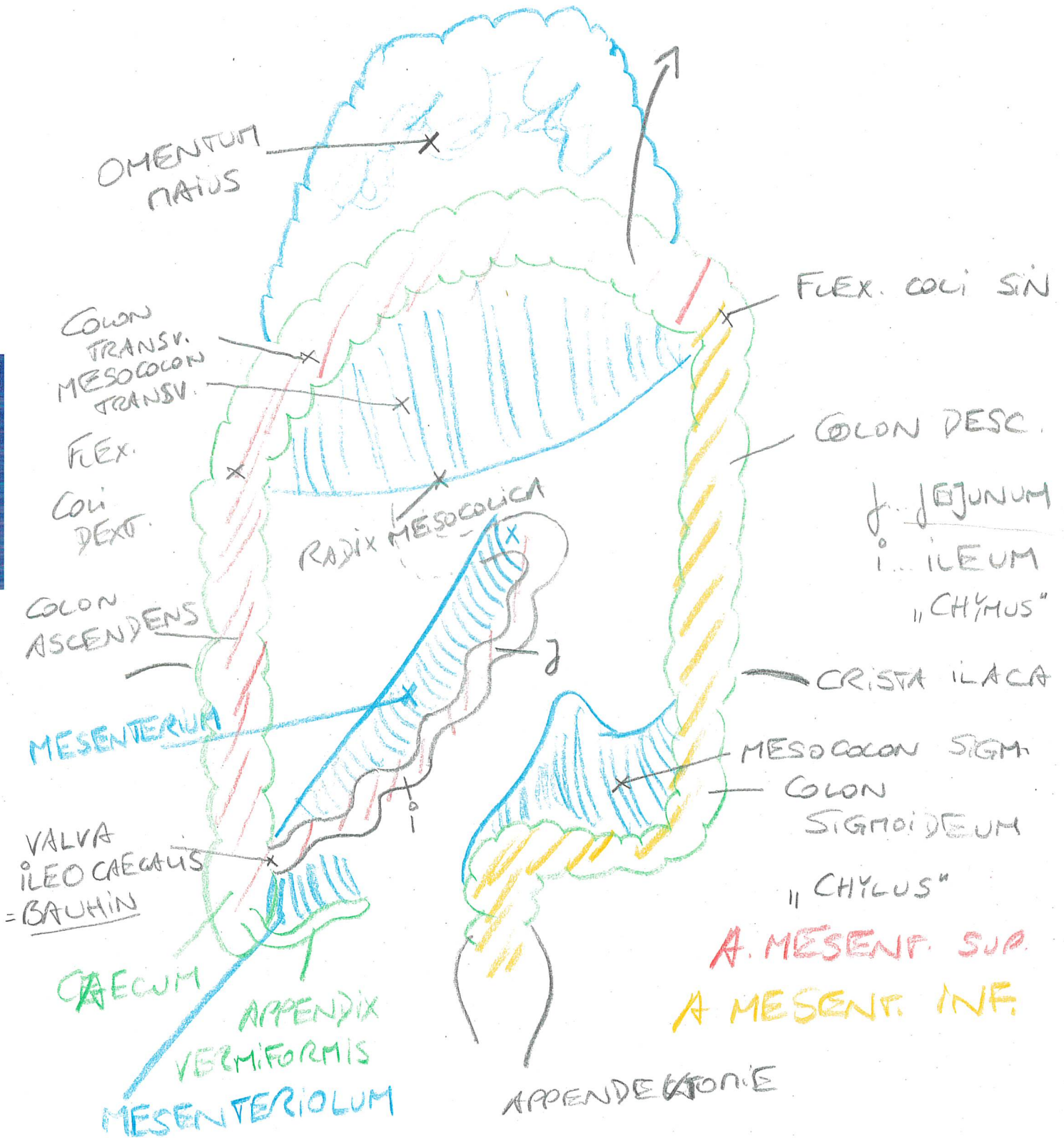


PANCREAS:

EXOKRIN: VERDAUUNGSENZYME
↳ DUOD.

ENDOKRIN: „INSULAE PANCREATICAE“
LANGERHANS: [CORPUS / CAUDA]
INSULIN
GLUCAGON

UNTERBAUCH:



DUODENUM:

- Plicae Circulares: ~2cm
Kerkring 2,5x
- Villi Intestinales: Zotten
~2mm 10-15x
- Mikrovilli: 100x

ILEUM: LYMPHFOLLIKEL [PEYER PLAQUES]

COLON: - Plicae Semicirculares

- HAUSTRAE

- APPENDICES EPIDIDICAE

- TRENIEN

RECTUM:

V. LAT.

